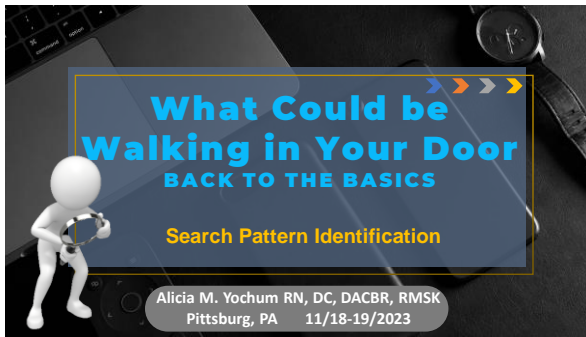

1



2



3

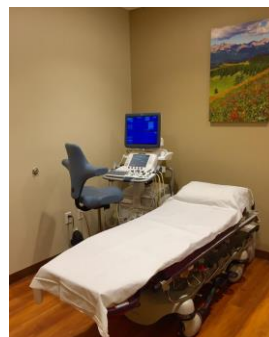Logan University



4

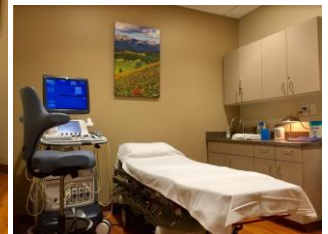

5

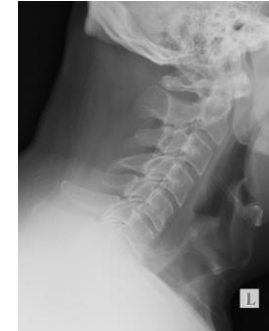

6

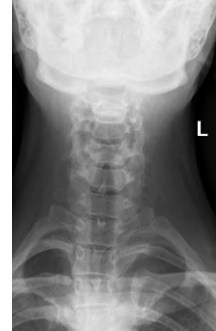Touchstone Imaging



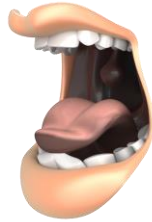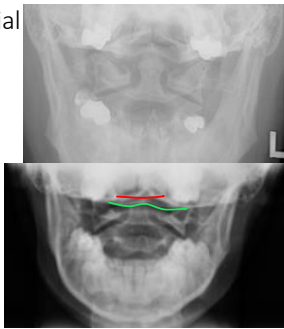
7



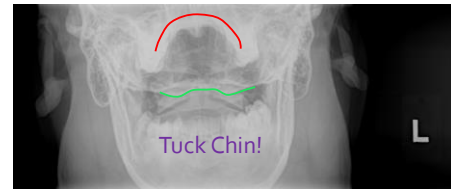
8



Atlanto-axial
APOM

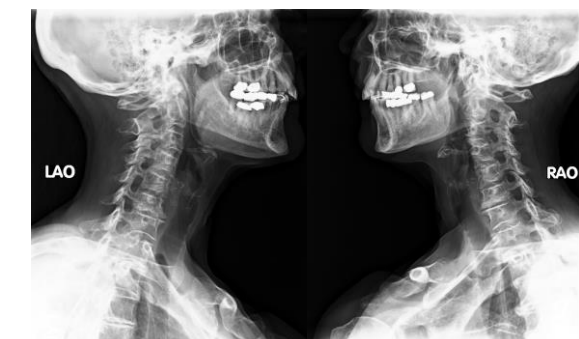

Bad Positioning

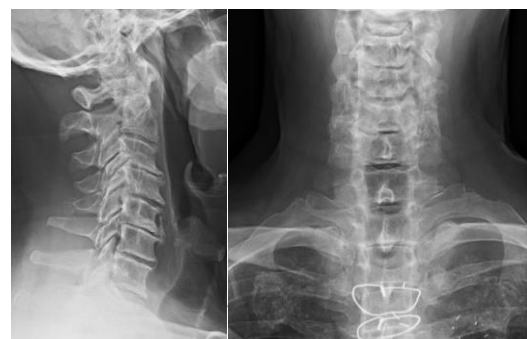


9

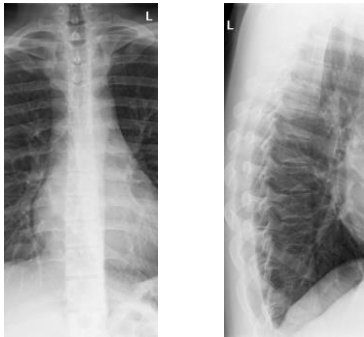
10



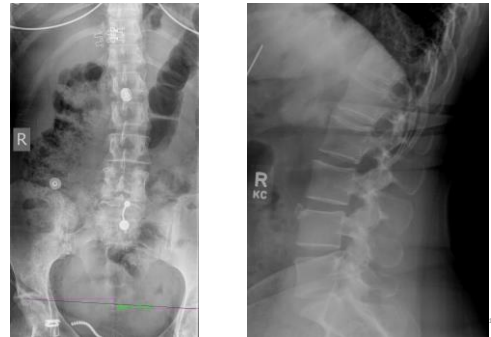11



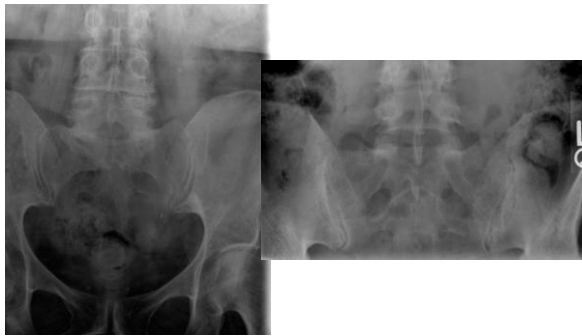
12



13



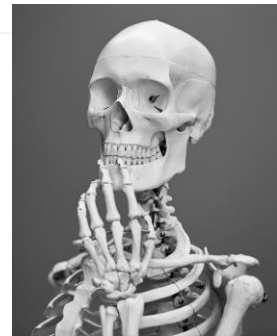
14



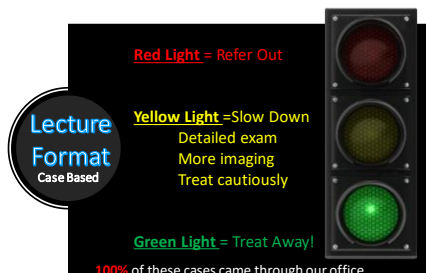
15

Purpose...

- Trends in chiropractic
- "Those patients won't come to my office"
- Choosing wisely guidelines



16

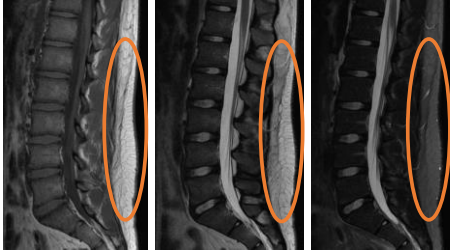


17

MRI Basics

Sequence	Water	Fat
<u>T1</u>	Black – Low	White – High
<u>T2</u>	White – High	Black – Low
<u>STIR</u>	White – High	Black – Low

18

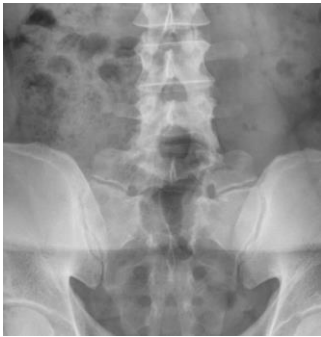

19



35 year old male-
Low back pain

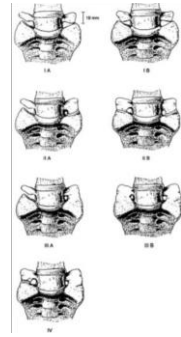
20



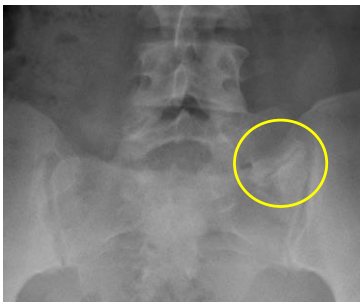
21

Transitional Segment

- Can get degenerative disease in accessory articulations
- Bertolotti syndrome



22

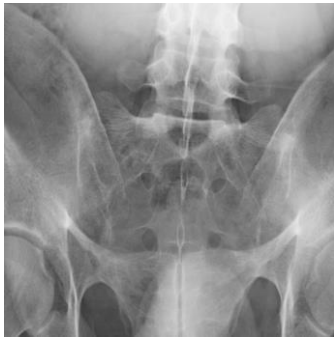

23

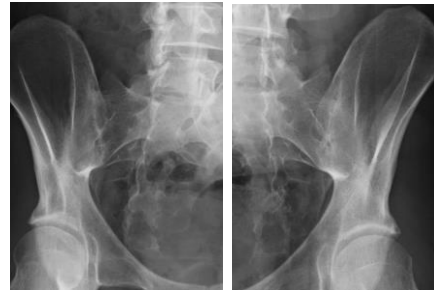

36 year old Male
with chronic low
back pain

24



25



26



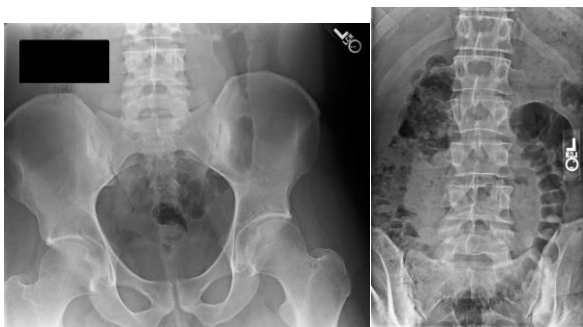Differential Diagnosis

- Follow Up?

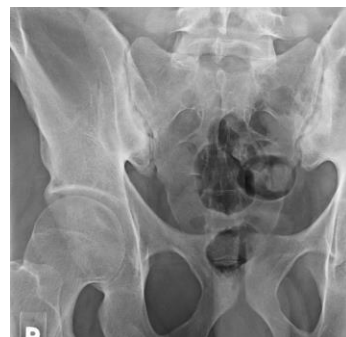27



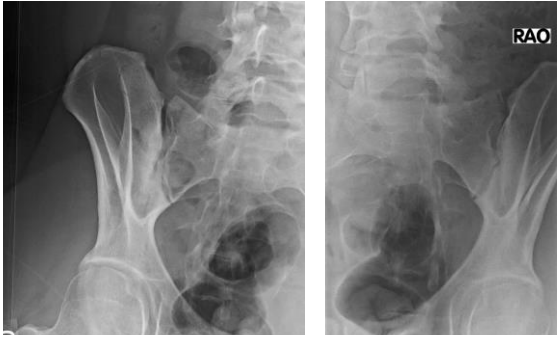28



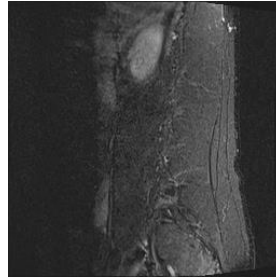
29



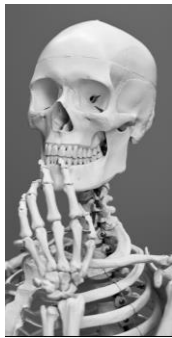30



31



32



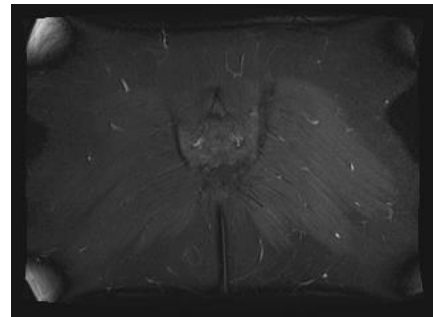
Differential Diagnosis?

- Tumor
- Inflammatory
 - Infection
 - Arthritis

NEXT STEPS?...



33

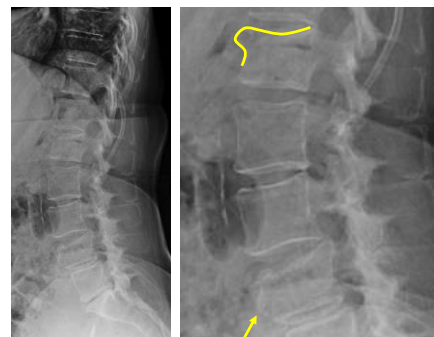


34



72 year old Female
fell shoveling snow

35

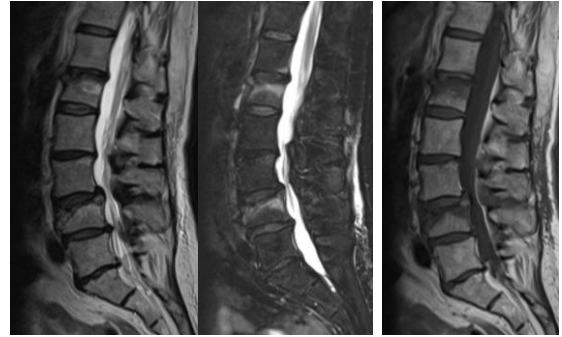


36

MRI Basics

Sequence	Water	Fat
T1	Black – Low	White – High
T2	White – High	Black – Low
STIR	White – High	Black – Low

37



38

Compression Fracture- Acute

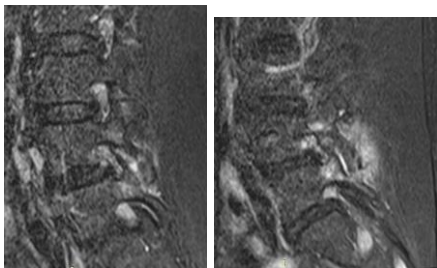
Kyphoplasty
Vertebroplasty

39

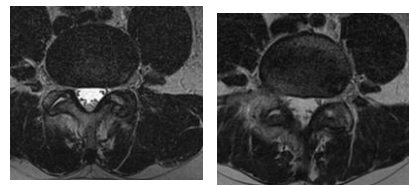
39

62 year old male
Low Back Pain

40



41



42

43

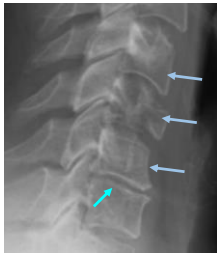
44



45 year old Male with neck pain following placing a box up on a shelf

Presented stating that "something was out and he just needed an adjustment"

Only exam finding was neck pain with slightly delayed reflexes
Doctor had a "bad feeling"



45



Differential Diagnosis

• Follow Up?

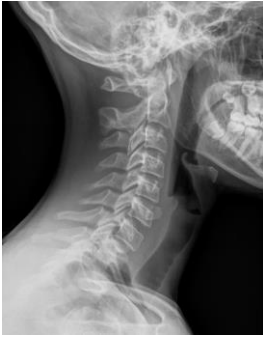46

47

48



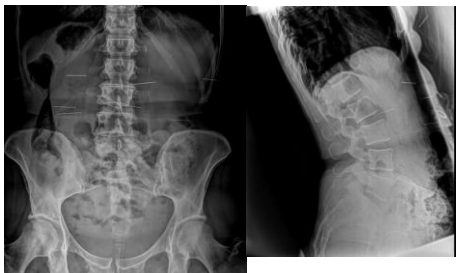15 yo Sharp CT junction pain post golfing



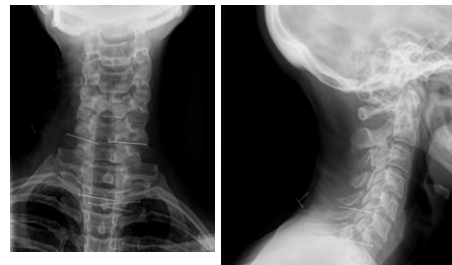
Clay Shovelers Fracture

49

50



51

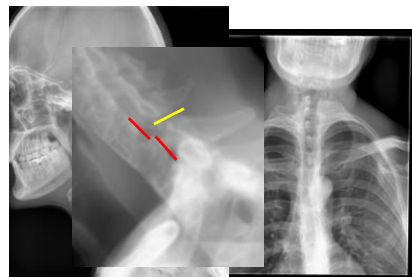


52

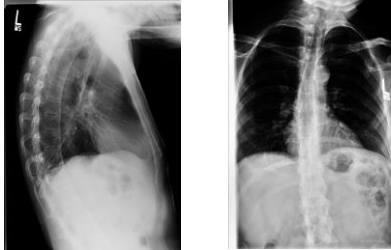


56yo Male with
neck pain
following MVA
earlier that day

53



54



55

Adjustment of the upper cervical spine was performed

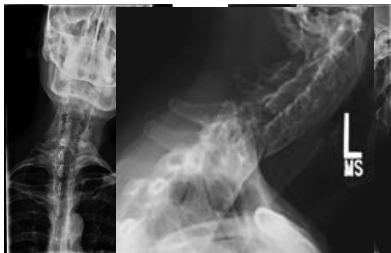Patient was sent home and he became nauseous and was vomiting that evening

His pain became progressively worse over a period of 5 days

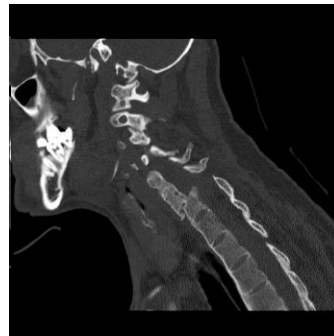He then presented to the emergency room



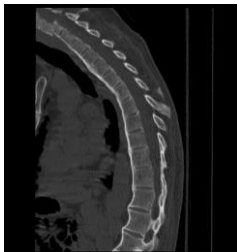56



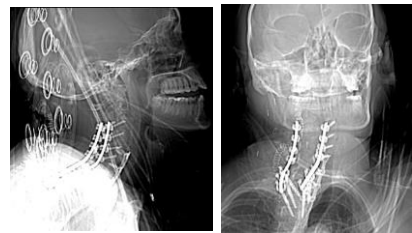
57



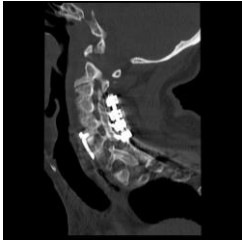
58



59

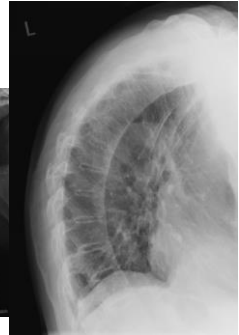
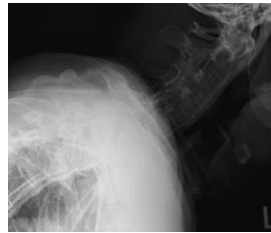


60



61

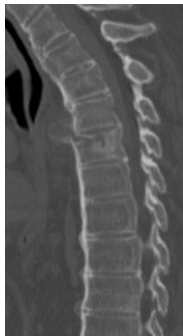MVA-69 year old



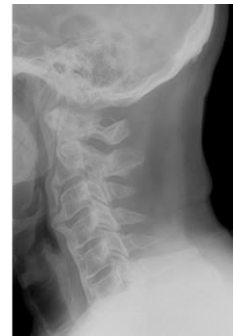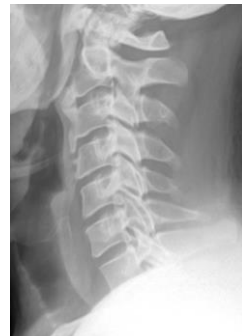62

AS-Fracture

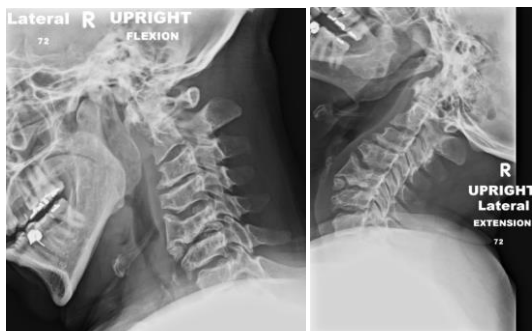- Carrot Stick Fracture
- Andersson Lesion



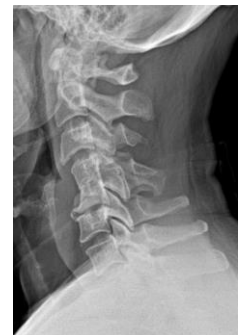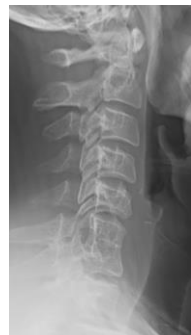63



64



65



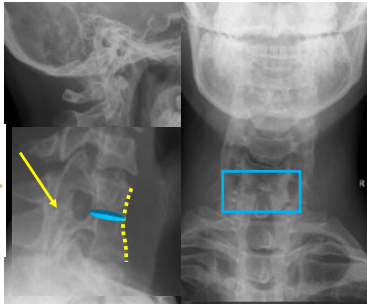
66

Blocked Vertebrae

- Anterior vertebral body and posterior facet and laminae fusion
- Remnant disc
- Wasp Waist Deformity



- Fusion of Multiple vertebra indicates Klippel-Feil Syndrome



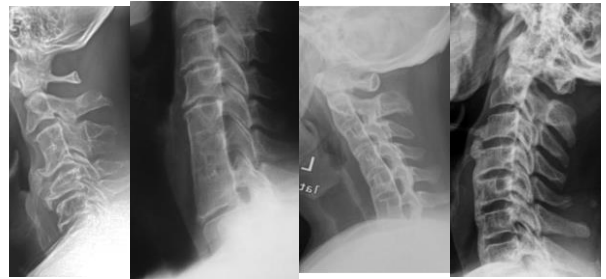67

Congenital

Surgical

AS

DISH

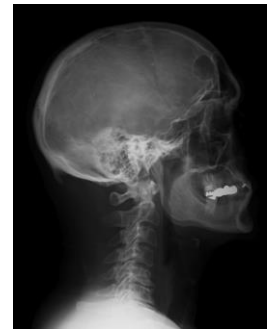
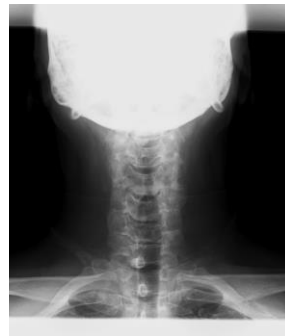
68

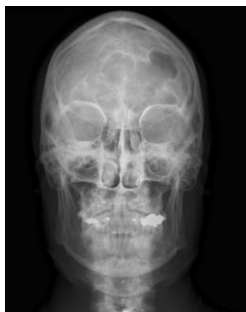

55yo male with neck pain
following MVC

69



70

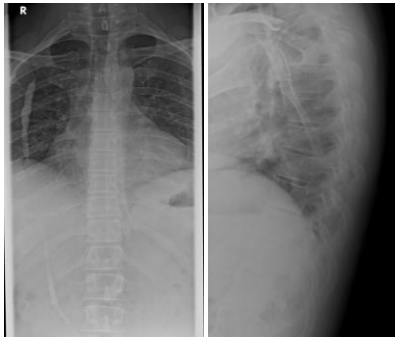

71



38 year old Male with mid
back pain

72



73



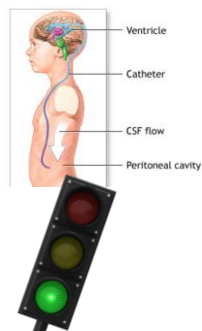
Differential Diagnosis

• Follow Up?

74

DDX

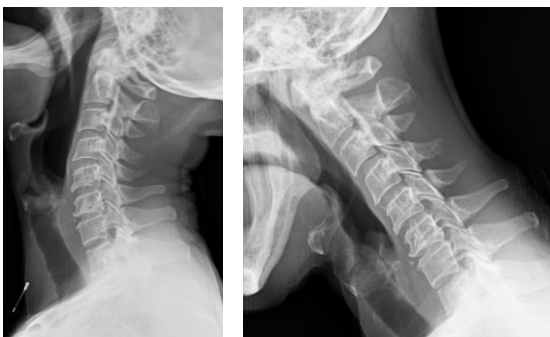- External clothing artifact
- Surgical artifact
- Calcified ventriculoperitoneal (VP) shunt



75

52 year old female
with neck pain

76



77

Ossification of the Posterior
Longitudinal LigamentCentral canal stenosis?
Cord Compression?

78



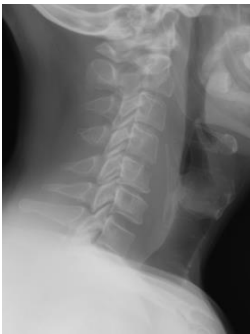50 year old male with neck pain
Hit on the head with garage door a few weeks prior

79

Physical Examination

- BP: 70/41
- Pulse: 118
- No standard orthopedic tested noted in the records (foraminal compression, soto hall, spurlings, jacksons)
- "Orthopedic test function to reproduce symptoms as this helps to correlate mechanism of pain"
- "Cervical flexion was restricted and elicited a pain reaction"
- Check next to C5 diagram as to subluxation on the left

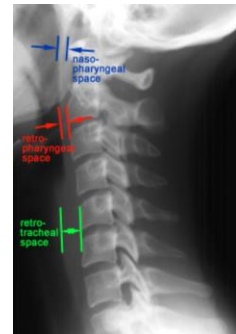80



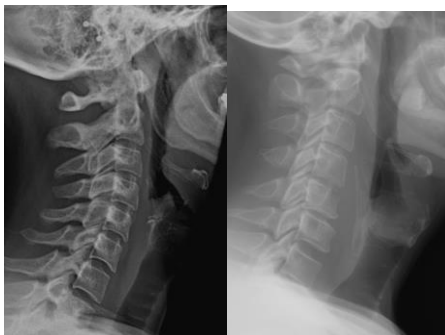81

- C2: 5-7mm Normal
- 11mm

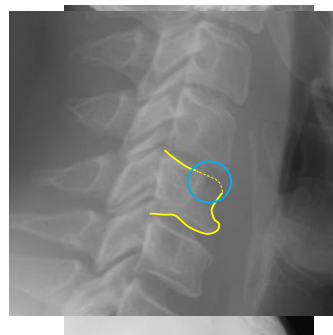
- C5: 20mm Normal
- 22mm



82



83

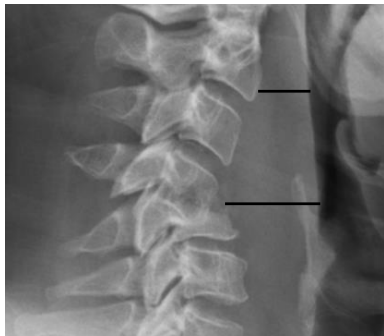


84

Patient was adjusted prone on the same day as the x ray

- Patient was treated 9 times in a 24-day period
- Minimal improvement with treatment
 - Patient said he thought the treatment was making him worse
 - The doctor never changed the type of treatment provided
- Chiropractor did tell the patient to go to the emergency room but the patient did not comply – no insurance
 - The doctor continued to treat the patient.
- After the fourth visit the patient reported that he was having so much pain that he had to hold his head up after the treatment

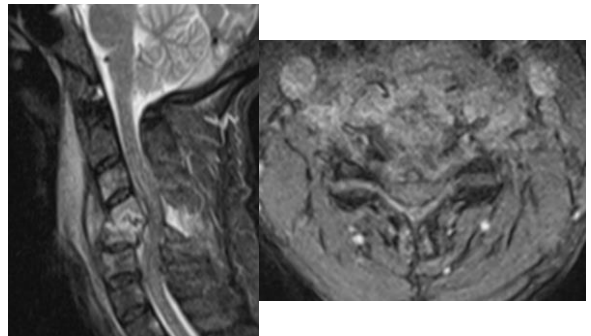
85



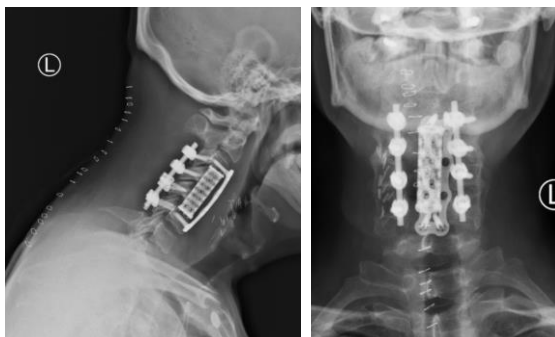
87

- After the final visit, the patient reported feelings of suicide due to his intense pain
- 2.5 hours after the final visit, the treating chiropractor sent a fax to a local pain doctor about the patient's intense pain and feeling of suicide
 - He never called the office to confirm receipt or to discuss the patient's case
- Approximately 5 days after the final visit the patient presented to the ER

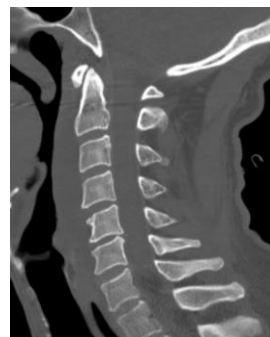86



88



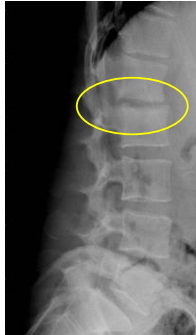
89



90

Spinal Infection

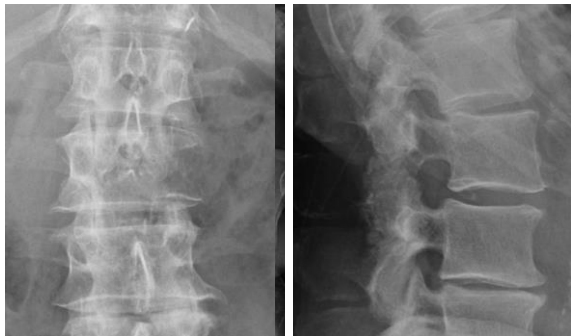- Endplate is infected first then moves to the disc
 - Endplate destruction in this case with initial prevertebral swelling
 - X ray can be negative for 2-4 weeks
- Bimodal age
 - Pediatric
 - Over 50yo
- Remote other infection in about 25%
- Present with
 - Back pain in over 90%
 - LESS COMMON fever UNDER 20%
- Staphylococcus Aureus most common – 60%
- Single level- 65%



72 Year old Male. Low back pain after golfing. Swelling around L3 on the left

91

92



93

METASTASIS

Additional history...
Esophageal cancer



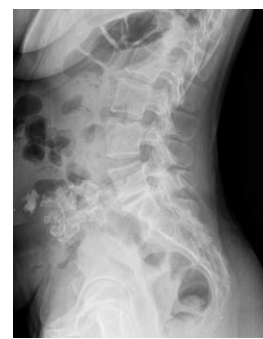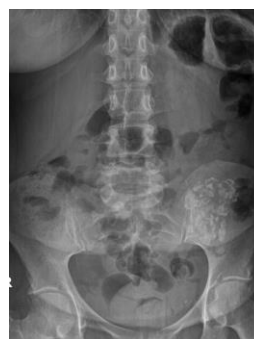94



55yo Female with
history of MVC

No other history provided

95



96

Failed Kidney Transplant

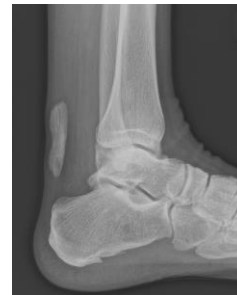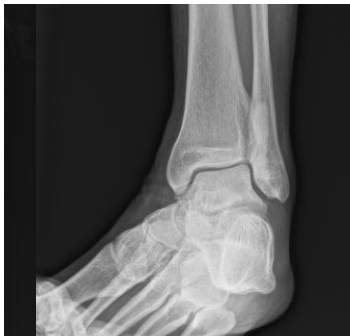- Can be related to renal osteodystrophy
- Osteomalacia
- Wide SI joints and pubic symphysis
- Rugger Jersey
- Salt and pepper skull



62 yo male ankle
stiffness and reduced
ROM

97

98



99

100

HADD in Achilles tendon

- Likely related to prior trauma
- May or may not be currently painful
- When this large could be causing reduced ROM and function



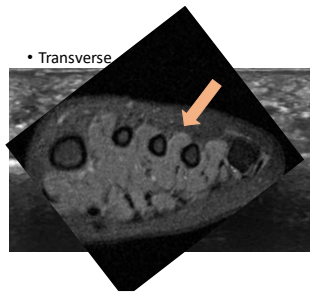
Patient feels like there is
a rock in their shoe at
the ball of their foot and
they have some
numbness between the
 $\frac{1}{4}$ toes

101

102

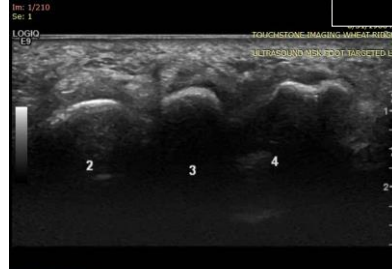
Morton's Neuroma

- >3mm is abnormal
- Mulder Sign
 - Palpable click resulting from displacement of the intermetatarsal mass on lateral compression
- Displacement is visible on US



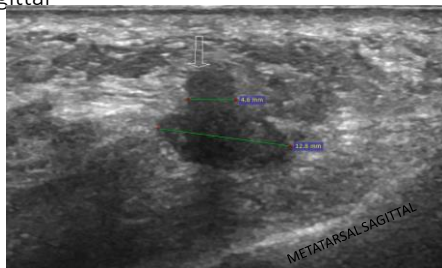
103

Lateral Squeeze/Compression- Mulder



104

Sagittal

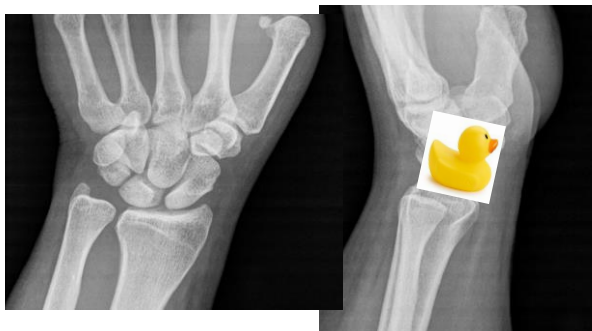

105

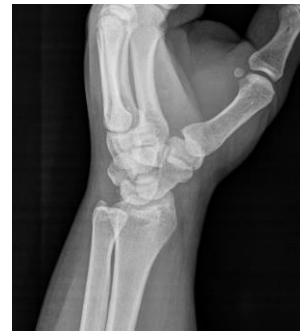

40 yo with wrist pain
following trauma

106



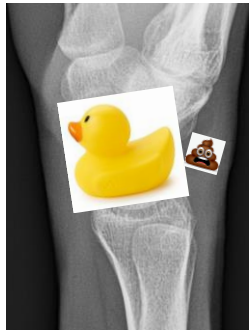107



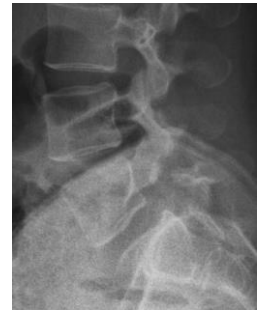108

Triquetral avulsion fracture

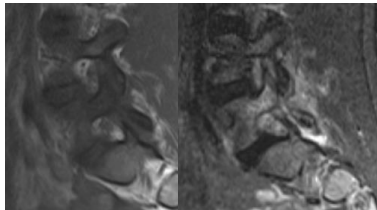
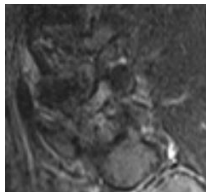
- Second most common fracture of the wrist.



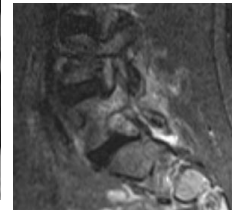
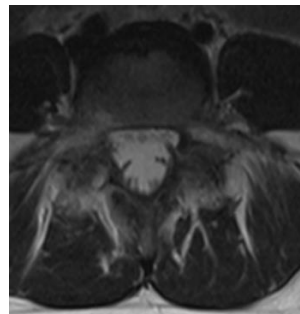
109



110



111



112

Boston Overlap Brace

The Boston Overlap Brace (B.O.B.) is a versatile, low-priced, easy-to-apply, medium-duty method for treating most indications where back pain is evident. It is highly recommended as an alternative where other bracing methods have been ineffective.

The B.O.B. features a unique anterior opening with a 3"-4" overlap. This is normally made with 1/8" thick low-density polyethylene unlined but can be made with different types of plastic and liner. This permits a wide range of adaptability to a variety of body configurations. The B.O.B. kit includes a pre-made Velcro closure with a formable spring steel inserts for adjustment of abdominal pressure.



Indications:

- Spondylolisthesis
- Spondylolysis
- Lumbar Fusion & Fracture
- Severe back pain

Benefits:

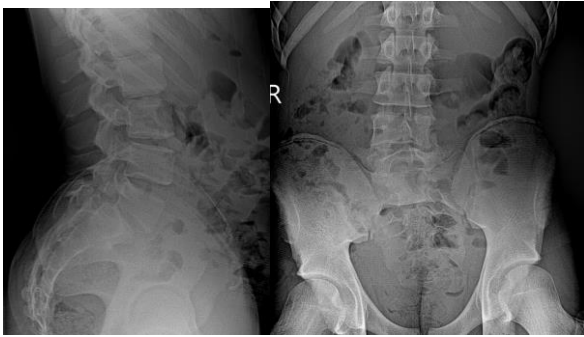- Custom to measurements, cast, or CAD scan.
- Lightweight

113

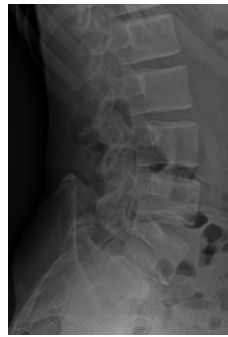16 yo Football player

Acute LBP after coming down on a players helmet.

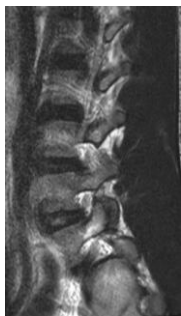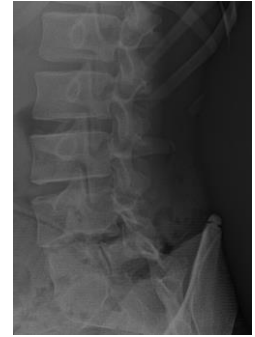114



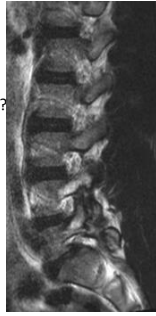115



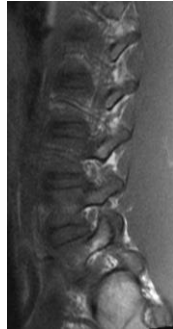116



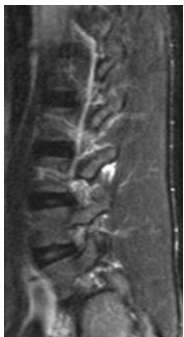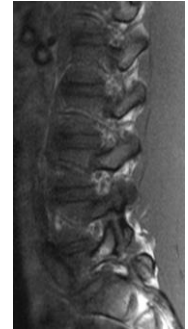• What's in there?



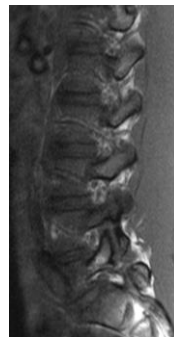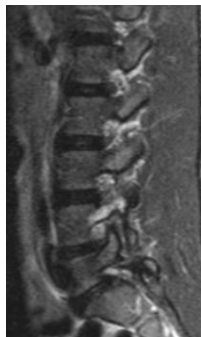117



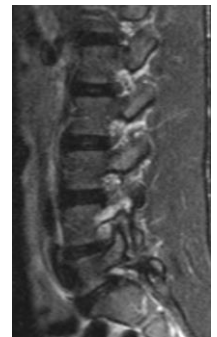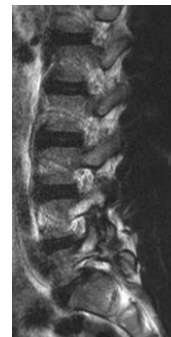118



119



120

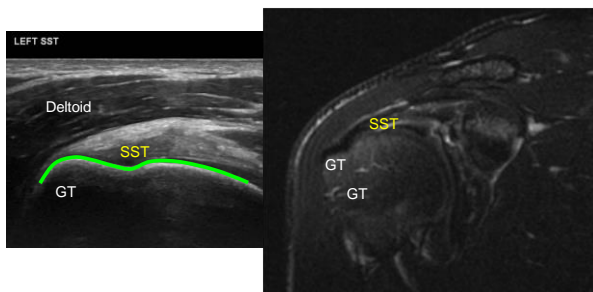


Inactive L5
Pending L4

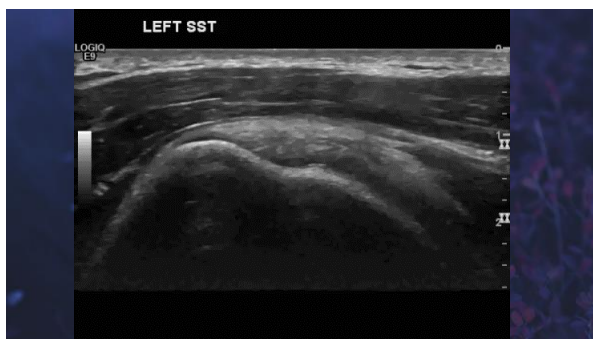


45 year old with shoulder pain
negative x rays

121

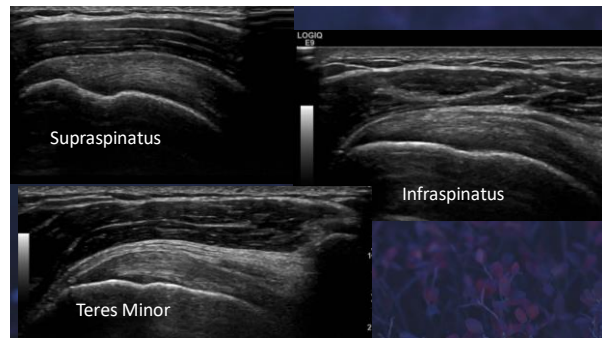


123

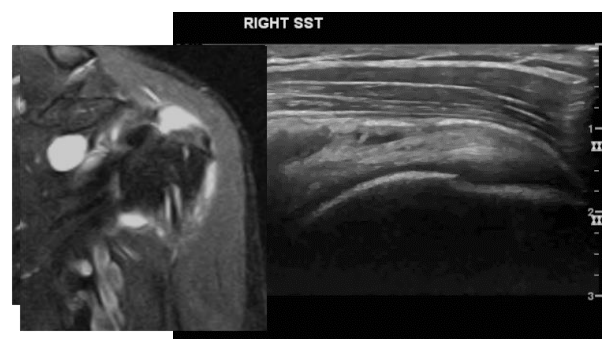

125

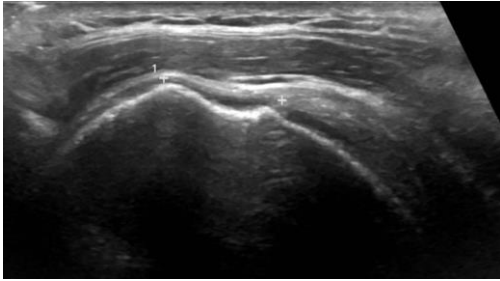
122



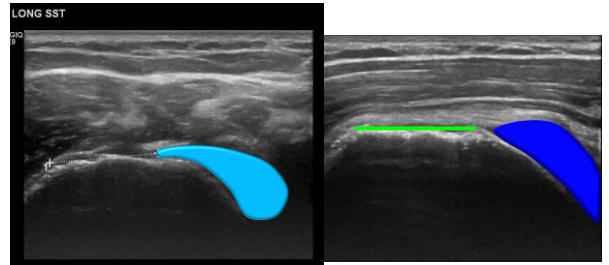
124



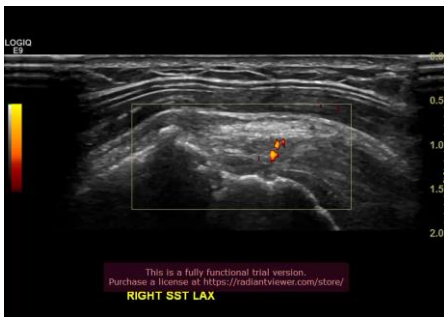126



127



128

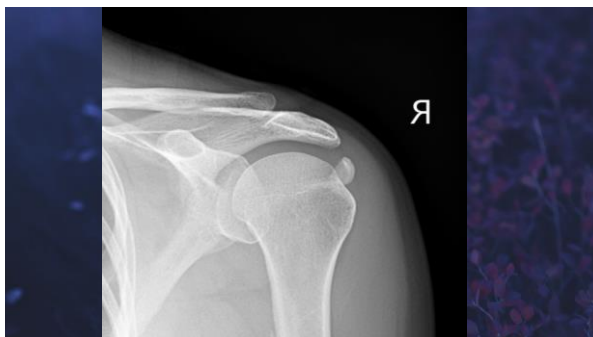


129



54 Year old with reduced
abduction and pain

130



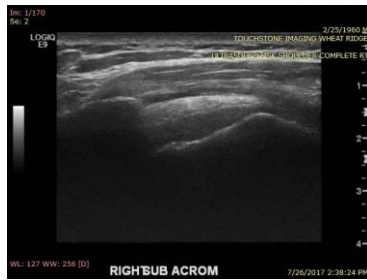131

Subacromial Impingement Evaluation

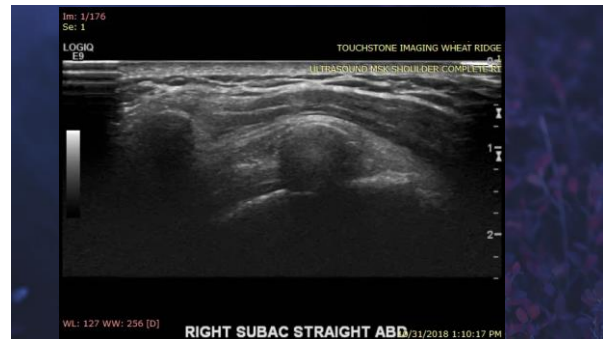


132

Subacromial Impingement Evaluation



133



134